

# Laparoscopy Surgical Treatment of Caesarean Scar Ectopic Pregnancy (CSEP): Case Report

## Tratamento de Gestação Ectópica em Cicatriz de Cesárea por Laparoscopia: Relato de Caso

DUARTE MIGUEL RODRIGUES RIBEIRO<sup>1</sup>; GLADIS MARIA RODRIGUES RIBEIRO<sup>1</sup>; PAULO COSSI<sup>1</sup>; THIAGO PAREJA DOS SANTOS<sup>1</sup>; MÁRCIA FREIRE<sup>2</sup>

<sup>1</sup> Doctor Duarte Miguel Ribeiro's Private Clinic and Department of Gynecology, Hospital São Luiz, São Paulo, Brazil; <sup>2</sup> Federal University, São Paulo UNIFESP-EPM, São Paulo, Brazil.

### ABSTRACT

Cesarean scar ectopic pregnancy (CSEP) is a rare condition, with serious clinical consequences, which requires fast and accurate diagnosis. The most appropriate treatment aims to reduce maternal morbidity with preservation of fertility. We present a case of Cesarean scar ectopic pregnancy in a patient with a recent history of tubal pregnancy with vaginal bleeding, sudden hemodynamic instability, and high levels of  $\beta$ HCG. Ultrasonography revealed a well encapsulated gestational mass, growing from the anterior wall of the uterus. The patient underwent laparoscopic treatment, lasting 140 minutes, with complete removal of the trophoblastic tissue, repair of the scar defect, control of the blood loss, and without the need for blood transfusion. Laparoscopy using a centripetal approach was effective in the addressing the ectopic pregnancy, as well as safe in controlling the bleeding and avoiding serious complications.

**Key words:** Cesarean section. Laparoscopy. Ectopic Pregnancy. Diagnosis. Differential diagnosis. Ultrasonic diagnosis.

**Braz. J. Video-Sur, 2013, v. 6, n. 3: 000-000**

Accepted after revision: february, 13, 2013.

### INTRODUCTION

**C**aesarean scar ectopic pregnancy (CSEP) is a rare condition with varied symptoms and high morbidity, whose early and correct diagnosis requires a high level of suspicion.<sup>1,2</sup> It is defined as a pregnancy separate from the endometrial cavity and completely surrounded by myometrium and scar tissue. The most likely mechanism postulated for its development is the migration of gestational tissue through a microscopic tubular channel caused by previous surgical trauma.<sup>1-3</sup>

Although the transverse uterine section is a very common procedure, CSEP occurs rarely.<sup>4-6</sup> There is no relationship with maternal age or parity, and it remains unclear whether there is relationship with the number of prior Cesarean sections the woman has had or with a short interval between surgery and CSEP, suggesting that incomplete healing might have contributed to ectopic implantation.

Incidence is estimated at 1:1900 to 1:2226 pregnancies, and represents 6.1% of ectopic

pregnancies among women with prior C-sections.<sup>3</sup> The increasing number of reports of CSEP in the literature is due to the increased number of cesarean deliveries, as well as the wide use of transvaginal ultrasound as a diagnostic method.<sup>2,4,6</sup>

Mild vaginal bleeding is the earliest symptom, but 37% of the cases of CSEP are asymptomatic when diagnosed.<sup>3,6</sup> Depending on the gestational age and the direction of growth of the gestational sac, blood loss may be more pronounced and accompanied by abdominal pain, and may lead to high risk clinical events such as uterine rupture and uncontrollable bleeding.

The initial differential diagnosis can be challenging, despite well-defined sonographic criteria such as: an empty uterine cavity and cervical canal, development of the gestational sac in the anterior part of the isthmus surrounded by myometrium and scar tissue, and absence of myometrium between the bladder and the gestational sac. Although transvaginal ultrasound and  $\beta$ HCG measurement can offer a high level of suspicion, ongoing abortion and cervical pregnancy still remain in the differential diagnosis.<sup>5</sup>

There is general consensus that Caesarean scar ectopic pregnancies should be immediately terminated.<sup>1-7</sup> Due to the rarity of this situation, however, there is no scientific evidence as to what is the best method for doing so.<sup>5, 7</sup> Below we describe the laparoscopic procedure using a centripetal approach for the treatment of Caesarean scar ectopic pregnancies.

## CASE REPORT

The patient is a 36 year old, gravida 4, para 2, ectopic tubal pregnancy 1, who presented to our service with amenorrhea for 45 days, sudden onset of vaginal bleeding, fainting, mild abdominal cramps, and a positive pregnancy test. She had undergone two cesarean deliveries 3 and 6 years earlier and a dilation and curettage followed by laparoscopic surgery for treatment of a right tubal ectopic pregnancy three months prior to presentation. Pelvic examination revealed a blood-tinged cervix, a slightly enlarged retroverted uterus, without adnexal masses.

Transvaginal ultrasound examination revealed an empty uterine cavity and cervical canal, the presence of vascularized amorphous mass implanted in the anterior wall of the uterus at the level of the isthmus. The serum beta-human chorionic gonadotropin (βHCG) level was 4481 mIU/ml, and hemoglobin 10.5 g/dl. Hemodynamic parameters were stable.

Magnetic Resonance imaging (MRI) with the introduction of aqueous gel vaginally showed that the thickness of the uterine wall between the bladder and the gestational sac was thinner than the adjacent wall and revealed a mass invading the anterior uterine wall in the topography of scar of the previous cesarean section without involvement of the cervical canal. Doppler ultrasound revealed extensive vascularity surrounding the gestational sac. These findings were compatible with the diagnosis of Cesarean scar ectopic pregnancy.

In the course of the work-up the patient presented intense genital bleeding associated with hemodynamic instability and she was promptly taken to the operating room for urgent surgical treatment. The patient was placed in supine position with arms alongside the body; compression stockings and pneumatic boots were placed. Laparoscopy was initiated with the patient in Trendelenburg at 35 degrees under general anesthesia.

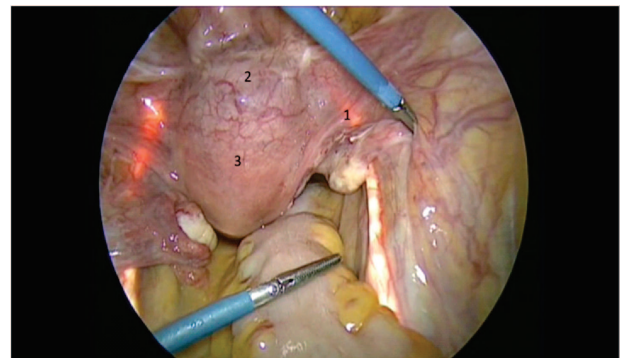
### Step 1: Cystoscopy and Laparoscopy

Cystoscopy with bilateral ureteral catheterization was performed; the correct anatomic position was confirmed by transillumination (Figure 1). A Verres needle was inserted through a transumbilical incision and pneumo-peritoneum was established with CO<sub>2</sub> at maximum pressure of 20 mmHg. An 11 mm bladeless trocar was inserted into the abdominal cavity and the abdominal organs visualized.

A 5 mm trocar was inserted 4 cm above the pubis symphysis toward the pelvic cavity and two others were positioned at the level of the anterior superior iliac crest, lateral to the inferior epigastric vessels in the right and left iliac fossa. After placing the trocars, the intracavity pressure was stabilized at 12 mmHg. The retroverted uterus was slightly enlarged with bulging of the anterior wall at the level of the vesico-uterine reflection. A mass arising from the serosa was detected at the level of the scar of the cesarean section.

### Step 2: Hemorrhage Control

Transient extrapelvic fixation of the ovaries with 3-0 polypropylene suture (Prolene) exposed the lateral compartment and provided access to the iliac arteries (IA). The internal iliac arteries (IIA) were identified as were the ureters by transillumination. A 4 cm longitudinal incision in the peritoneum following the path of the IIA which had been dissected was performed and at 2.5 cm from its/their bifurcation they were isolated with 0 polyglactin (Vicryl) followed by torsion of the suture secured with a 5 mm clip (Duarte Technique) (Figure 2). No medication was injected at the site.



**Figure 1** - Ureters catheterized and transilluminated (1), uterine bulge (2), uterus (3).

### Step 3: Monobloc resection and correction of the scar defect

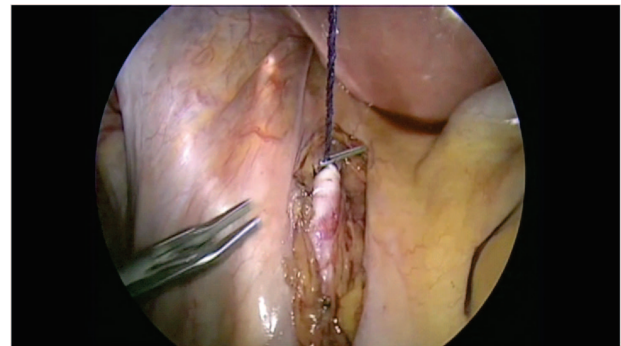
The transilluminated ureters defined the lateral anatomical borders. The peritoneum was incised to the bladder wall (previously distended with 500 ml of 0.9% saline and 1 ml of methylene blue) at the level of the isthmus-cervical transition. The uterine serosa was incised to isolate the bladder in a ventral orientation and the surgical borders (ventral bladder, broad ligaments and uterine body) around the bulging uterus were defined. Elliptical excision of the mass and the affected uterine wall were performed, removed en bloc (centripetal approach) (Figure 3). Hemostasis was attained using bipolar energy and the uterine defect was repaired using 2-0 polyglactin (Vicryl) in two planes with continuous suture and 3-0 polydioxanone (PDS II) suture for closing the serosa (Figure 3). The gestational sac was removed in an endobag and the blood flow in the IIA was restored.

The operative time was 140 minutes. Estimated blood loss was 100 ml; there was no need for blood transfusion. Anatomic pathology revealed ovular and partially necrotic decidua remains amid fibrino-hematic material, fragments of connective tissue and smooth muscle adjacent to the remains of surgical sutures and vascular ectasias. The  $\beta$ HCG decreased to 3073 mIU/ml on the first postoperative day. The patient postoperative course was uneventful and she was discharged on the third post-operative day. Her menstrual flow became regular the following month. The patient was accompanied for one year after treatment. She took an oral contraceptive use; there was no pregnancy during this period.

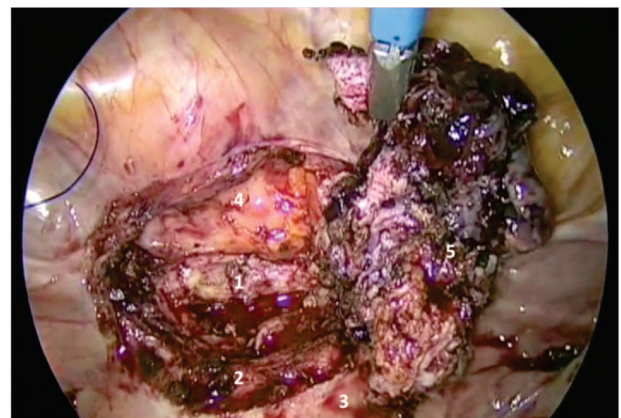
## DISCUSSION

When compared to the large number of Caesarian sections performed, CSEP remains as a rare event. Due to serious clinical events associated, much has been discussed about the importance of early diagnosis and appropriate treatment of CSEP. The failure of initial treatment can lead to uncontrollable bleeding and hysterectomy, which increases the maternal morbidity and deprives the patient of the possibility of future pregnancy.

Although ultrasound criteria for the diagnosis of CSEP – such as non-detection of the fetus within the uterine cavity between, finding the gestational sac between the anterior uterine wall and the bladder, and the loss of continuity of the uterine wall in the sagittal



**Figure 2** - Internal Iliac Arteries (IIA) were dissected, isolated and temporarily tractioned.



**Figure 3** - Proximal myometrium (1), distal myometrium (2), uterus (3), bladder (4) and mass with the affected uterine wall resected "en bloc" (5).

view – are well established, the differentiating spontaneous abortion, cervical pregnancy, and CSEP still is challenging. Yang Q, et al. reported that in 39 cases of CSEP, about 16 patients were misdiagnosed and were treated incorrectly, which resulted in persistent vaginal bleeding to severe hemorrhage.<sup>7</sup>

The combination of two diagnostic imaging modalities can help with the early diagnosis of CSEP.<sup>6</sup> In the present case we used sonographic criteria for diagnosis and MRI for confirmation and a detailed understanding of the situation before operating. Ultrasound and hysteroscopy together can provide information for an early and accurate diagnosis.<sup>1</sup>

Transvaginal ultrasound can detail the course of growth of the gestational mass, ranging from superficial implantation with growth into the cervical space to deep implantation into the myometrium with growth to visceral serosa. Hysteroscopy has the advantage of visualizing the distribution of blood vessels in the deployment bag gestacional.<sup>7</sup> Due to the risk of miscarriage or injury to optic nerve of the fetus



after the tenth week of gestation, however, Khunda et al, believe that hysteroscopy should be used only after the diagnosis of CSEP has been confirmed.<sup>8</sup>

Medical management remains the first choice, with or without invasive procedures,<sup>2,9-10</sup> but has variable success and several disadvantages.<sup>5</sup> Local infiltration of Methotrexate (MTX) and ultrasound-guided aspiration of the embryo may be a treatment option in CSEP cases with a gestational age of six to eight weeks. Despite the local action of MTX and disappearance of the embryo, a residual placenta and gestational sac structures are still detected by ultrasound for about two months, which together with vaginal bleeding may cause physical and emotional discomfort.<sup>10</sup>

An unsatisfactory response to MTX may occur due to delayed absorption, caused by the very scar tissue where the gestational sac is implanted, complicating the clinical picture, resulting in persistent vaginal bleeding and increasing the risk of pelvic infection.<sup>9</sup> Medical management still leaves the Cesarean scar, a scar with a demonstrated predisposition to ectopic pregnancy<sup>11</sup> and necessitates adherence to ongoing laboratory and ultrasound monitoring. Surgical interventions are still needed if medical treatment fails, still result in a slow decline in  $\beta$ HCG concentration, with the risk of uterine rupture and massive hemorrhage.<sup>4</sup>

Curettage is contraindicated because the trophoblastic tissue is outside the uterine cavity (and thus is not reached by the curette), may break the gestational sac, injure the myometrium, and lead to uncontrollable bleeding.<sup>4</sup> Catastrophic bleeding can occur with aspiration procedures or curettage, because myometrium with scar tissue and the cervix have less capacity for fibromuscular contraction to control bleeding. Yang Q et al observed a lower hemoglobin concentration in patients from other services who were misdiagnosed and treated initially with procedures that lead to major blood loss, compared those were correctly diagnosed with a CSEP.<sup>7</sup>

In patients with previous Cesarean section, CSEP should be excluded prior to performing procedures such as curettage.<sup>1</sup> There is a suspicion that CSEP cases diagnosed after subsequent curettage may have occurred due to perforation of the prior scar tissue by the curettage, drawing/taking trophoblastic tissue outside the uterine cavity, resembling an ectopic implantation and a false positive diagnosis.<sup>4</sup>

Although medical management is used, surgical procedures – including laparotomy<sup>12</sup> or laparoscopy<sup>1,4,5</sup> – emerge in other reports as the first treatment option. In patients who wish to conceive later, the surgical procedure can be used alone as the first option or together and immediately following the use of MTX.<sup>11</sup> Surgery may correct the scar defect, however there still is no scientific evidence regarding the best approach for preserving fertility. Wang et al. reported that among 28 patients in whom pregnancy after treatment of CSEP was considered possible, seven had documented pregnancies; four had been treated surgically and three medically.<sup>5</sup>

Hysteroscopy in conjunction with laparoscopy proved to be a reliable method for diagnosis and treatment of CSEP with preservation of the uterus.<sup>1</sup> Chao et al. used hysteroscopy for diagnosis and suggested that the best treatment option for embryos growing toward the uterine cavity would be transcervical resectoscopy, with laparoscopy recommended in cases of deeper implantation or growth outside of the uterine cavity.<sup>9</sup>

Laparoscopy can confirm the diagnosis of CSEP and, despite being an invasive treatment, is well tolerated by patients. It affords rapid resolution of the situation, without the disadvantages of medical management, such as the persistence of high levels of  $\beta$ HCG and the slow absorption of the gestational mass.<sup>4,5</sup>

In order to preserve the uterus and diminish or avoid bleeding, Yang MJ & Jeng MH combined laparotomy and uterine artery embolization, which resulted in less intraoperative bleeding, with secure closure of the uterine damage, preservation of fertility, and removal of the entire material for pathological examination.<sup>12</sup> The injection of a local vasoconstrictor<sup>4,5</sup> or ligation of the uterine arteries, combined with the intra-abdominal pressure effect of the pneumoperitoneum may lead to less intraoperative bleeding.<sup>5</sup> We use the technique described by the author, here referred to as the “Duarte Technique”, which entails the isolation and traction of the internal iliac arteries, which allows control of intraoperative bleeding and permit the complete restoration of the uterine blood flow later.

Preoperative cystoscopy and catheterization of the ureters allows the identification of the ureters, making their dissection unnecessary and thereby reducing the possibility of iatrogenic injuries. Because of the anatomic distortion, directly approaching the gestational

mass may predispose to an increased risk of uncontrollable bleeding and vesico-ureteral injuries.

Only surgery offers the opportunity to remove the gestational sac and repair the defect. Although the recurrence of CSEP is rare, the resection of old scar can further reduce this possibility and (as long as there are no complications) achieve recovery of function faster than with medical management.<sup>6</sup>

## CONCLUSION

A consensus regarding the best management for the treatment of CSEP can be achieved when we relate the initial clinical and laboratory picture, gestational age, and the direction of growth of the trophoblastic tissue, with the treatment the achieves the lowest maternal morbidity, preservation of fertility, and quickness in resolving the situation. The future

analysis only cases with primary diagnosis of CSEP, excluding possible false positive cases or cases of prior therapeutic complications can help to design the best approach to be taken in each case.

The conservative laparoscopic treatment requires trained staff and adequate conditions, but has been shown to be an effective alternative in the treatment of patients with CSEP. Laparoscopy may be performed to confirm the diagnosis, remove gestational tissue and restore the uterine scar with good control of bleeding, while preserving the reproductive capacity of the patient.

Catheterization of the ureters prevented intraoperative complications. Similarly, the technique used to control bleeding proved to be effective and safe, allowing for the complete restoration of blood flow after the surgical procedure was completed.

---

## RESUMO

A gestação ectópica em cicatriz de cesárea apresenta-se como uma condição rara, com sérios eventos clínicos, que requer diagnóstico rápido e preciso. O tratamento mais adequado visa diminuir a morbidade materna com preservação da fertilidade. Apresentamos um caso de gravidez ectópica em cicatriz de cesárea em uma paciente com antecedente de gravidez tubária recente, com sangramento vaginal súbito, instabilidade hemodinâmica e níveis elevados de  $\beta$ HCG. A ultrassonografia revelou massa gestacional bem encapsulada, crescendo a partir da parede anterior do útero. Foi submetida a tratamento videolaparoscópico, com duração de 140 minutos, retirada completa do tecido trofoblástico, correção do defeito cicatricial, com perda sanguínea controlada e sem a necessidade de transfusão de sangue. A laparoscopia com abordagem centrípeta mostrou-se eficaz no tratamento da gravidez ectópica, assim como segura no controle de sangramento e complicações graves.

**Palavras chave:** Cesariana. Laparoscopia. Gravidez ectópica. Diagnóstico. Diagnóstico diferencial. Diagnóstico ultrassônico.

---

## REFERENCES

1. Lee CL, Wang CJ, Chao A, et al. Laparoscopic management of an ectopic pregnancy in a previous cesarean section scar. *Hum Reprod.* 1999; 14: 1234-1236.
2. Tan G, Chong YS, Biswas A. Cesarean scar pregnancy: a diagnosis to consider carefully in patients with risk factors. *Ann. Acad. Med. Singapore* 2005; 34:216-219.
3. Ash A, Smith A, Maxwell D. Cesarean scar pregnancy. *BJOG* 2007; 114:253-263.
4. Wang YL, Su TH, Chen HS. Operative laparoscopy for unruptured ectopic pregnancy in a cesarean scar. *BJOG* 2006; 113:1035-1038.
5. Wang YL, Su TH, Chen HS. Laparoscopic management of an ectopic pregnancy in a lower segment cesarean section scar: a review and case report. *J. Minim. Invasive Gynecol.* 2005; 12:73-79.
6. Maymon R, Halperian R, Mendlovic S, et al. Ectopic pregnancy in cesarean section scars: the 8 year experience of one medical centre. *Hum Reprod.* 2004;19:278-284.
7. Yang Q, Piao S, Wang G, et al. Hysteroscopic surgery of ectopic pregnancy in the cesarean section scar. *J. Minim. Invasive Gynecol.* 2009;16:432-436.
8. Khunda A, Tay J. Cesarean scar pregnancy. *BJOG* 2007; 114:1304.
9. Chao A, Wang TH, Wang CJ, et al. Hysteroscopic management of cesarean scar pregnancy after unsuccessful methotrexate treatment. *J. Minim. Invasive Gynecol.* 2005;12:374-376.
10. Hwu YM, Hsu CY, Yang HY. Conservative treatment of cesarean scar pregnancy with transvaginal needle aspiration of the embryo. *BJOG* 2005; 112:841-842.
11. Hasegawa J, Ichizuka K, Matsuoka R, et al. Limitations of conservative treatment for repeat cesarean scar pregnancy. *Ultra Sound Obst. Gynecol.* 2005;25:310-311.

12. Yang MJ, Jeng MH. Combination of transarterial embolization of uterine arteries and conservative surgical treatment for pregnancy in a cesarean section scar. *J. Reprod. Med.* 2003;48:213-216.

**Corresponding Author:**

DUARTE MIGUEL RODRIGUES RIBEIRO

Clínica Dr. Duarte Miguel Ribeiro

Rua Dr. Eduardo de Souza Aranha 99, Conjuntos 51/61

Itaim Bibi - São Paulo - SP - Brasil

Fax: 55 11 3846-7679

E-mail: dmrr@terra.com.br